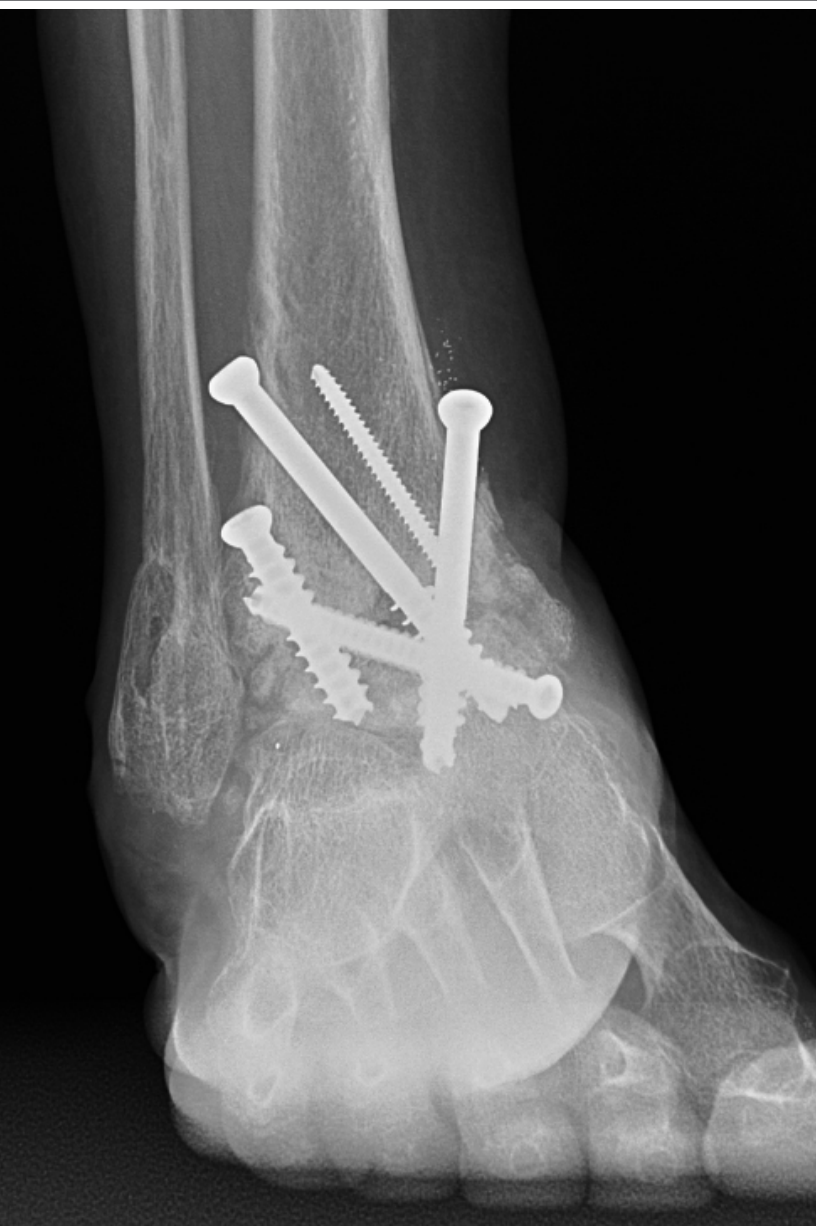

Open Right Ankle Fracture and Talus Fracture

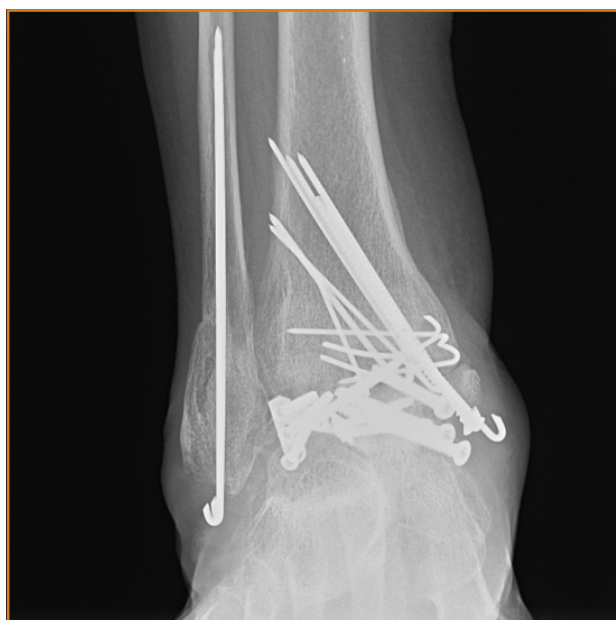7.0mm & 8.0mm Cannulated Fastener System

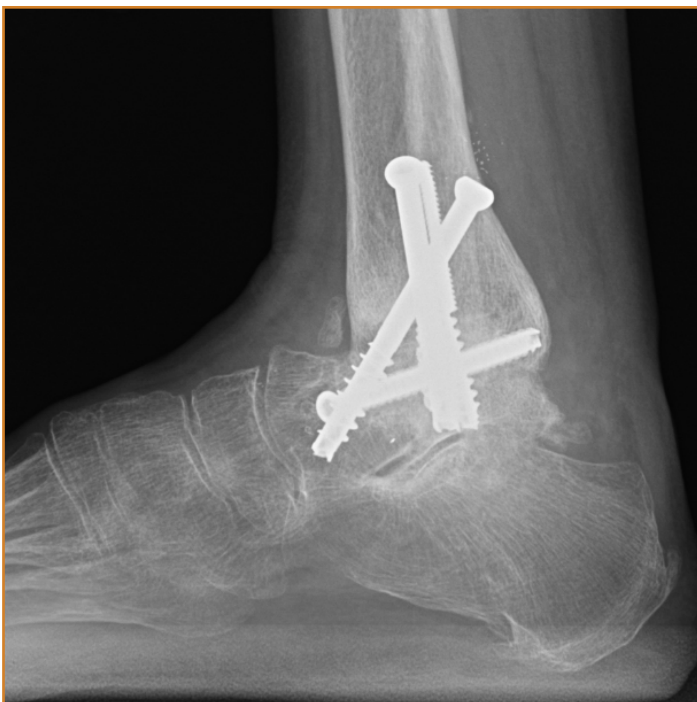Case Study | Dr. Justin Haller



Patient History

A 66 year old female involved in a motor vehicle versus dump truck accident traveling 40 MPH. Among other injuries, the patient sustained an open right ankle fracture and talus fracture. The injuries were originally fixed 1.5 years prior to presentation by a surgeon from an outside institution. The patient predominantly had anterior ankle pain and a CT scan demonstrated a relatively well preserved subtalar joint. Ankle range of motion was limited to a 10 degree arc.





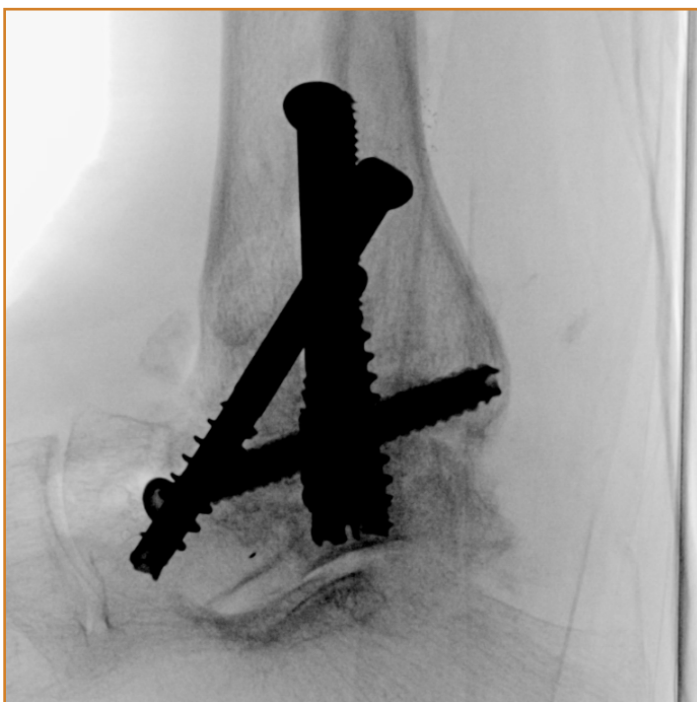
Treatment

Given the patient's age, activity level, and amount of ankle motion, she was indicated for a tibiotalar fusion. The pre-operative plan was to remove as much of the prior hardware as possible and perform a tibiotalar fusion with at least three cannulated screws.

Her prior medial and lateral approaches to the talar neck were utilized to remove the implants from the ankle and talus. A distractor was placed, and the tibial plafond and talus were exposed to denude any remaining cartilage and to drill 2.0mm holes into subchondral bone. The desired coronal and sagittal alignment was obtained and several 2.7mm guide wires were placed across the tibiotalar joint. OsteoCentric 7.0mm cannulated screws were placed over the wires and the wires were removed.

Follow-Up

The patient was discharged from the hospital on post-operative day 1. She was casted at 2 weeks post-operatively and remained non-weightbearing for a total of 8 weeks. At 3 months follow-up, the patient was able to ambulate in a CAM walking boot.



Clinical Advantages of UnifiMI

1. The OsteoCentric cannulated 7.0mm fasteners allow for improved bone capture and engagement in bone with poor quality. Following screw and wire removal from the talus and tibia, the amount of available bone was diminished, making it more challenging for the screw fasteners to achieve purchase. This was critical in this case as the fasteners had to remain only or solely in the talar body of the talar body and neck to preserve the subtalar joint.
2. The UnifiMI technology allows for significant compression to be achieved across the tibiotalar fusion site without engaging the cortex of the subtalar joint.

These materials contain information about the products that may or may not be available in any particular country or may be available under different trademarks in different countries. The products may be approved or cleared by governmental regulatory organizations for sale or use with different indications or restrictions in different countries. Products may not be approved for use in all countries. Nothing contained on these materials should be construed as a promotion or solicitation for any product or for the use of any product in a particular way which is not authorized under the laws and regulations of the country where the reader is located.



75 West 300 N, Suite 150
Logan UT, 84321
Phone: 1-800-969-0639
info@osteocentric.com
osteocentric.com